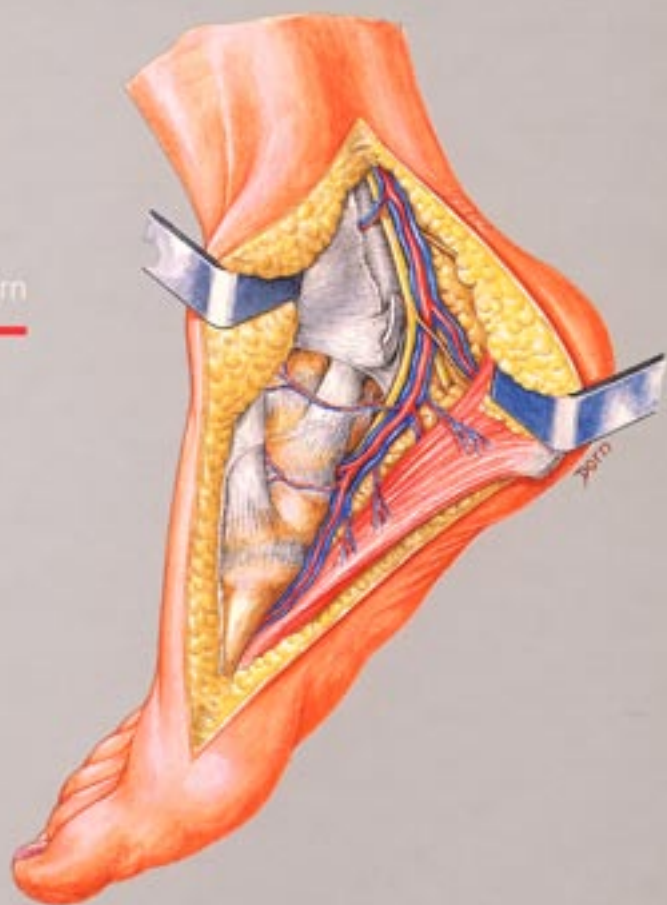


An Atlas of Surgical Exposures of the Lower Extremity

Alain C Masquelet
Christopher J McCullough
Raoul Tubiana

With
Ian S Fyfe
Leslie Klenerman
Emile Letournel

With illustrations by Léon Dorn



MARTIN DUNITZ

Contents

Preface viii
Artist's preface ix

1 Pelvic girdle 1

Introduction 2
Acetabulum: ilioinguinal (Letournel) approach 17
Acetabulum: iliofemoral approach 25
Acetabulum: extended iliofemoral (Judet) approach 29
Acetabulum: posterior (Kocher-Langenbeck) approach 36
Acetabulum: triradiate (Dana Mears) approach 43
Acetabulum: lateral 'U' (Ollier, modified S n gas) approach 48
Sacroiliac joint: posterior approach 52
Pubic symphysis: midline incision 57
Pubic symphysis: transverse (Pfannenstiel) incision 59
Obturator foramen and ischium 62
Iliac crest 65
Posterior iliac crest bone graft 69

2 Hip 73

Anterior (Hueter) approach 74
Extended anterior (Smith-Petersen) approach 79
Anterolateral (Watson-Jones) approach 83
Lateral (Gibson) approach 86
Lateral transgluteal (Hardinge) approach 91
Posterior (Moore) approach 94
Medial (Ludloff) approach 98

3 Femur 101

Introduction 102
Anatomical considerations 102
Proximal and middle third: posterolateral approach 106

Distal third of the femur: lateral approach 111
Distal quarter of the femur: medial approach 115
Distal two-thirds of the femur: anteromedial approach 119
Femoral shaft: anterolateral approach 123
Femoral shaft: posterior approach 127

4 Knee 137

Introduction 138
Anatomy 138
Medial parapatellar approach 147
Lateral parapatellar approach 150
Medial approach 152
Posteromedial approach 155
Lateral approach to the knee and proximal tibia 157
Posterior approach 164

5 Tibia and fibula 169

Introduction 170
Anatomy 170
Proximal third of the tibia: anterolateral approach 176
Midshaft of the tibia: anteromedial approach 178
Midshaft of the tibia: posteromedial approach 180
Midshaft of the tibia: anterolateral approach 183
Tibia and fibula: posterolateral approach 186
Lateral approach to the tibia: anterior to the fibula 191
Distal quarter of the tibia: posterolateral approach 195
Distal quarter of the tibia: anterolateral approach 199

Proximal and middle third of the fibula: lateral approach and lateral extended approach to the distal third of the fibula 203
Fasciotomy of the leg: introduction 209
Fasciotomy of the leg: anterolateral incision 210
Fasciotomy of the leg: posteromedial incision 211

6 Ankle and foot 213

Introduction 214
Anteromedial approach to the ankle 220
Anterolateral approach to the ankle 222
Anterior approach to the ankle 226
Posteromedial approach to the ankle 230
Posterolateral approach to the ankle 233
Transfibular approach to the ankle 237
Lateral approach to the subtalar joint and midtarsal joints 240
Lateral approach to the calcaneum 243
Dorsolateral approach to the foot 245
Dorsomedial approach to the foot 247
First tarsal column: dorsal approach 250
Exposure of the metatarsophalangeal joint of the great toe 252
Exposure of the metatarsal heads for resection 254
Approaches for the removal of digital neuromas 256
Plantar approach 256
Dorsal approach 257
Posteromedial approach to the Achilles tendon 259

7 Arteries and veins 261

Introduction 262
Anatomy of the arteries 262
Anatomy of the veins 272
Femoral artery: Scarpa's triangle 275
Femoral artery: Hunter's canal 278
Popliteal artery 282
Femoropopliteal junction: limited medial approach 282
Distal popliteal artery: limited medial approach 287

Popliteal artery: extended medial approach 291
Popliteal artery: posterior approach 294
Popliteal artery and bifurcation: lateral approach 298
Arteries of the leg 302
Posterior tibial artery: introduction 303
Posterior tibial artery: medial approach to the proximal segment 303
Posterior tibial and peroneal arteries: posterior approach splitting soleus 304
Posterior tibial artery: medial approach to the distal segment 308
Anterior tibial artery: proximal segment 311
Anterior tibial artery: distal segment 313
Dorsalis pedis artery 315
Posterior tibial and plantar arteries 318
Exposure of the long saphenous vein 321

8 Peripheral nerves 325

Introduction 326
Anatomical considerations 328
Lumbosacral plexus: lateral approach 339
Femoral nerve 344
Lateral cutaneous nerve of thigh 348
Obturator nerve 351
Sciatic nerve: introduction 353
Sciatic nerve: exposure in the buttock 353
Sciatic nerve: exposure in the thigh 356
Sciatic, tibial and common peroneal nerves: the popliteal fossa 361
Common peroneal nerve: posterolateral approach 365
Tibial nerve and its bifurcation: medial approach 368
Sural nerve 369

9 Skin and muscle flaps 371

Introduction 372
Vastus lateralis muscle flap 372
Soleus muscle flap 376
Gastrocnemius muscle flaps: introduction 380
Gastrocnemius muscle flaps: the medial head 380

| | |
|--|-----|
| Gastrocnemius muscle flaps: the lateral head | 384 |
| Fasciocutaneous saphenous flap | 387 |
| Dorsalis pedis flap | 390 |
| Medial plantar flap | 395 |
| Lateral supramalleolar flap | 401 |
| Select bibliography | 407 |
| Index | 408 |