
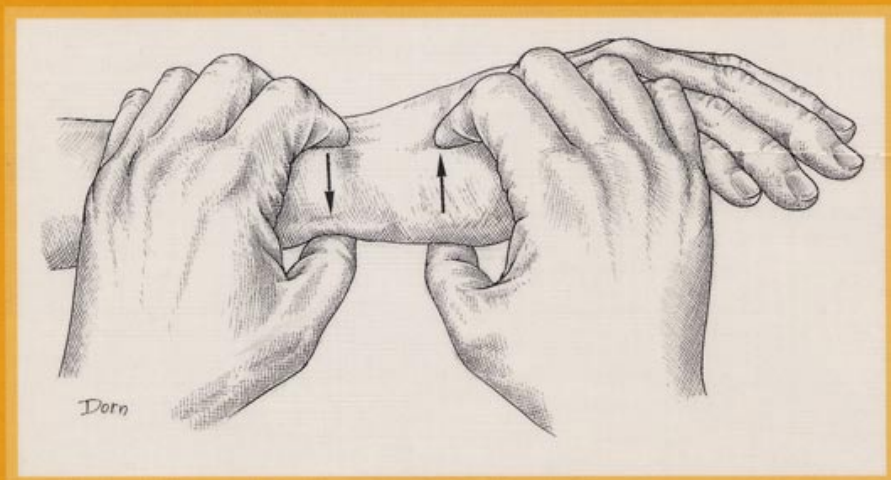


EXAMINATION OF THE HAND AND WRIST



Raoul Tubiana

Jean-Michel Thomine

Evelyn Mackin

MARTIN DUNITZ

CONTENTS

List of contributors	iv
Foreword	v
Preface	vii
Acknowledgements	viii
1 <i>Functional Anatomy</i>	1
1.1 Skeleton of the hand	4
1.2 Skeleton of the wrist	28
1.3 Movements of the hand and wrist	40
1.4 Skin cover	128
1.5 Functions of the hand	156
2 <i>Clinical Examination of the Teguments, the Skeleton and the Musculotendinous Apparatus</i>	175
2.1 Examination of the teguments, palmar aponeurotic lesions and trophicity	176
2.2 Examination of the bones and joints	185
2.3 Examination of the musculotendinous apparatus	205
3 <i>Imaging</i>	225
3.1 Radiological examination	225
3.2 Investigation of the circulation	243
4 <i>Examination of the Peripheral Nerve Functions in the Upper Limb</i>	261
4.1 Innervation of the upper limb and clinical features of nerve paralysis	262
4.2 Functional assessment of motor function	286
4.3 Sensibility evaluation	328
4.4 Signs of neural regeneration	355
References	371
Index	387