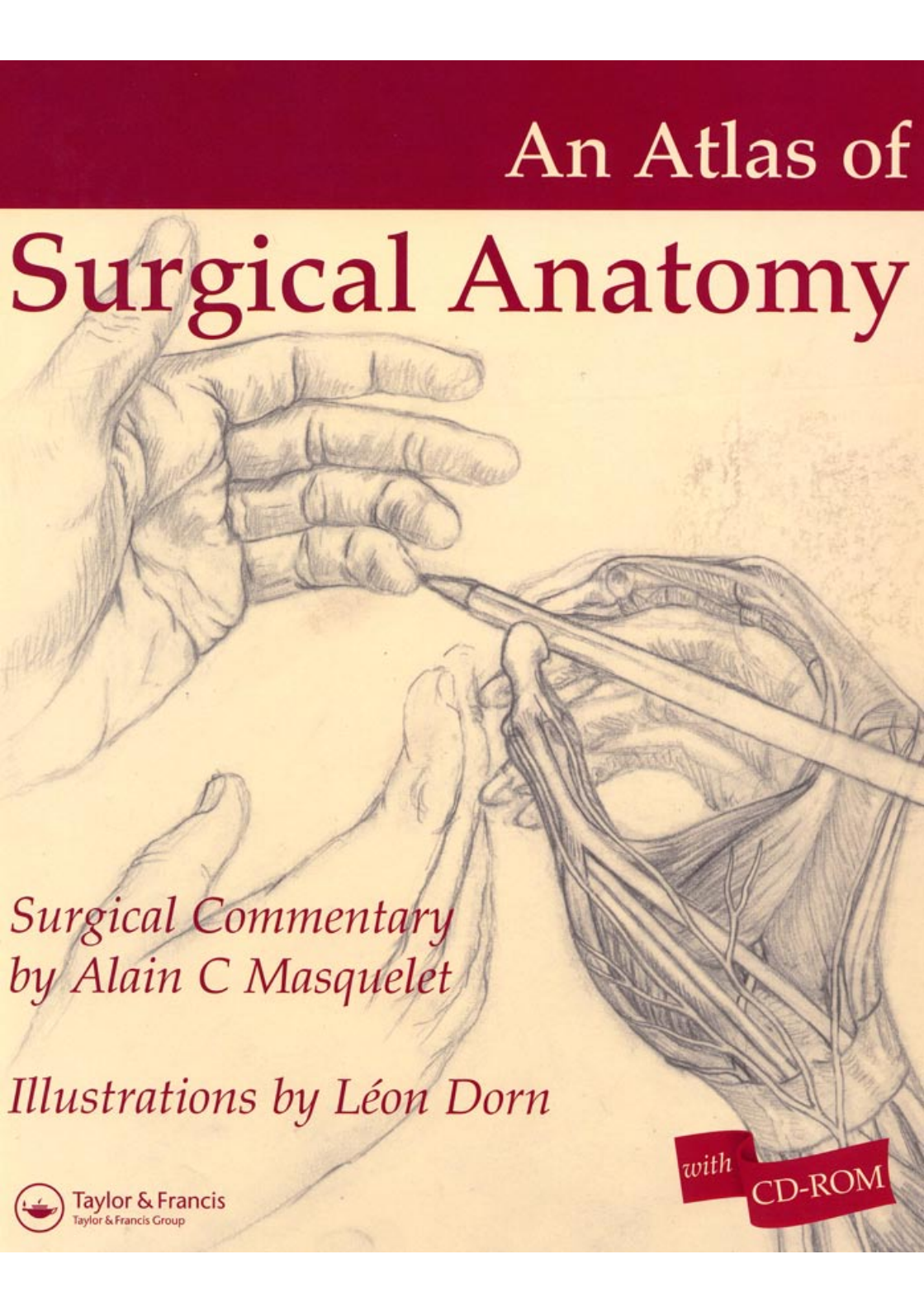


An Atlas of Surgical Anatomy

A detailed pencil illustration of a surgical dissection. A hand on the left holds a surgical instrument, possibly a retractor or dissector, which is being used to hold back muscle and soft tissue. On the right, another hand holds a long, thin surgical instrument, possibly a probe or a dissector, which is being used to explore or separate tissue. The dissection reveals underlying anatomical structures, including what appears to be a bone, muscle, and a network of blood vessels. The style is that of a classic anatomical drawing, with fine lines and shading to indicate depth and texture.

*Surgical Commentary
by Alain C Masquelet*

Illustrations by Léon Dorn



Taylor & Francis
Taylor & Francis Group

with

CD-ROM

Preface vii

Léon Dorn: A biographical note viii

Léon Dorn: Notes on method ix

1 Reconstructive surgery

The tree of flaps for the upper limb 2

Flap from the lateral head of

gastrocnemius 3

Soleus muscle flaps 5

Sural skin flap 8

Vascularised osteoperiosteal flap from the
femur 10

Vascularised fibula transfer 11

Lateral brachial flap 14

Forearm radial flap 16

Posterior interosseous flap 18

Pronator quadratus muscle flap 20

2 Hand and peripheral nerve surgery

Anatomy of the hand 24

The trapezium: volar approach 27

The 'boutonnière' deformity 31

Arthrolysis of the PIP joint 34

Protective flaps for the median nerve at the
wrist 36

Flexor digitorum superficialis transfer to the
thumb 38

Vascularised bone transfer from the metaphysis
of the second metacarpal 39

Dupuytren's disease 40

Surgery of the wrist 44

Pollicisation of the index finger 45

Brachial plexus 49

Exposure of the interosseous nerve 54

Exposure of the radial nerve at the
elbow 57

3 Gynaecological surgery

The lower approach of the prolapse and
the separation of the vagina and the
bladder 60

Treatment of genital prolapse after
hysterectomy 65

Surgical treatment of ectrocele 70

4 Urological surgery

Allotransplantation of the kidney 74

Surgery of renal lithiasis 79

Extrophy of the bladder in a young boy 81

Hypospadias surgery 86

Prosthesis for erectile function of penis 90

Amputation of the penis for sexual ambiguity:
feminisation 97

5 Abdominal surgery

Reconstruction of a urinary bladder 106

Gastrectomy 110

The liver 115

6 Surgery of the vertebral column

Transpleural approach to the dorsal rachis by
thoracotomy 120

Treatment of lumbar spondylolisthesis 122

Surgical treatment of scoliosis 126

Treatment of lumbar disc hernia: anterior
approach 129

7 Upper limb surgery

Sternoclavicular dislocation 134

Stabilisation of a shoulder prosthetic
implant 136

Cleidectomy 137

Osteosynthesis of a fracture of the
forearm 139

Anterior approach to the subacromial
space 141

Contents

Anterior approach to the glenohumeral joint 143
Axillary approach to the glenohumeral joint 147
Subdeltoid approach to the proximal metaphysis of the humerus 150
Anterior approach to the proximal third of the radius 151

8 Lower limb surgery

Anatomy of the posterior approach to the femoral shaft 154
Extended medial approach to the popliteal vessels 157
Anatomy of the knee 160
Anatomy of the lumbosacral plexus 162
Prosthesis of the patella 163
Repair of a rupture of the anterior cruciate ligament 167
Posterior approach to the posterior cruciate ligament 171

Allograft of patella and patellar ligament 173
Cross-section through the hip joint 176
Posterior approach to the acetabulum 177
Inguinal approach to the acetabulum 181
Extended iliofemoral approach to the acetabulum 186
Posteromedial approach to the ankle 190
Lateral approach to the subtalar and midtarsal joint 193

9 Miscellaneous

Muscular studies 195
Surgery of the ear: neurosurgery 199
Surgery of the middle ear 202
Tympanic graft 204
Paediatrics: Pavlick's harness 207
Congenital malformations 208
Detection of fetal anomalies 216
Dissection of the left heart 217
Dissection of the right heart 221

Index 225