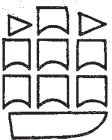


# The Hand: Diagnosis and Indications

**Graham Lister F.R.C.S.**

Assistant Clinical Professor of Plastic  
Surgery, University of Louisville,  
Kentucky, USA.  
Consultant Hand Surgeon,  
University of Louisville Affiliated  
Hospitals.

Foreword by Adrian E. Flatt M.D.



CHURCHILL LIVINGSTONE  
Edinburgh London and New York 1977

# Contents

1. Injury	1
The two stages of examination are detailed: the initial in the emergency room where the importance of surface anatomy, careful observation and systematic testing is emphasized: the second, surgical exploration, in which the choice of skin cover and the identification of all injured deep structures receive special attention.	
2. Reconstruction	46
A statement of the eight basic hand functions is followed by an assessment of how each anatomical component—skin, nerves, joints, tendons and vessels—individually and severally may impair performance of those functions.	
3. Compression	93
Differing factors produce compression neuropathy and these, together with the common elements of pain, sensory disturbance, motor loss and electrophysiological changes, are discussed before considering individually the compression syndromes which afflict the upper limb.	
4. Inflammation	117
Both acute and chronic inflammatory disorders are described, stress being laid in the former on the significant compartments of the hand and in the latter on disturbances of the musculotendinous units and on osteoarthritis of the carpus.	
5. Rheumatoid	133
An account of a system of regional examination which differs from that employed in non-rheumatoid patients is accompanied by those aspects of pathological anatomy which are required to understand the unique deformities of the rheumatoid hand.	
6. Swelling	166
A systematic approach to all swellings and ulcers of the hand is presented with a description of six selected lesions.	
Appendix: Muscle Testing	177
This Appendix illustrates the testing of all the muscles of the upper limb.	
Bibliography	189
Index	201